

MANAGEMENT AND CONTROL OF ISOTONIC CONTRACTION GENERATED STRESS: EVALUATION OF MASSETER MUSCLE DEFORMATION PATTERN BY MEANS OF ECOGRAPHY

A. BUSATO¹, G. BALCONI², V. VISMARA¹, L. BERTELE³, G. GARO⁴, D. DE GREGORIO⁵

¹ Medica Libra, Milano, Italy

² Department of Radiology, Hospital San Raffaele Turro, Milano, Italy

³ Fondazione Apostolo, Merate, Italy

⁴ President and Founder of Siach - The International Society of Surgical Anatomy

⁵ Director of Siach, Aesthetic Surgeon, Perugia, Italy

SUMMARY

Purpose. The objective of the following study is to observe the behavior of the six layers of the masseter during an isometric contraction at maximum exertion with the deformation pattern analysis method.

Materials and methods. This study has been conducted by use of an ultrasound machine (MicrUs ext-1H Telemed Medical Systems Milano) and a linear probe (L12-5I40S-3 5-12 MHz 40 mm) which allowed us to record a video (DCM) comprised of 45 frames per second. The probe was fixed to a brace and the patient was asked to clench their teeth as hard as possible, obtain the muscle's maximum exertion, for 5 seconds three times, with 30 seconds intervals in between. Both right and left masseter muscles were analyzed. Then we applied to the resulting video a software (Mudy 1.7.7.2 AMID Sulmona Italy) for the analysis of muscle deformation patterns (contraction, dilatation, cross-plane, vertical strain, horizontal strain, vertical shear, horizontal shear, horizontal displacement, vertical displacement). The number of videos of masseter muscles in contraction at maximum exertion due to dental clenching made during this research is around 12,000. Out of these we chose 1,200 videos which examine 200 patients (100 females, 100 males).

Results. The analysis of the deformation patterns of the masseter allows us to observe how the six layers of the muscle have different and specific functions each, which vary depending on the applied force (application point, magnitude and direction) so that we find it impossible to assign to one of the three sections of the muscle a mechanical predominance. Therefore it appears that the three parts of the muscle have specific and synergistic tasks

Key words: masseter muscle, ultrasound, strain, deformation analysis pattern method.



Introduction

Both dissection and ultrasound demonstrate that the structure of the masseter muscle is very complex, composed of three distinct parts and organized in layers (1): the superficial masseter is formed by two layers (internal and external), the middle masseter has only one layer and the deep masseter has three separate layers (outward, central and inward). When

speaking of the function of the muscle we generally refer to it as a whole and not as separate parts. The main functions it is responsible for are the elevation of the mandible and the generation of considerable force during the clenching of the dental arches, which can be as high as 90/100 kg per cm² (Figure 1).

The objective of the following study is to observe the behavior of the six layers of the masseter during an isometric contraction at maximum exertion (2) with the deformation pattern analysis method. The literature often postulates that the deep masseter has a pre-

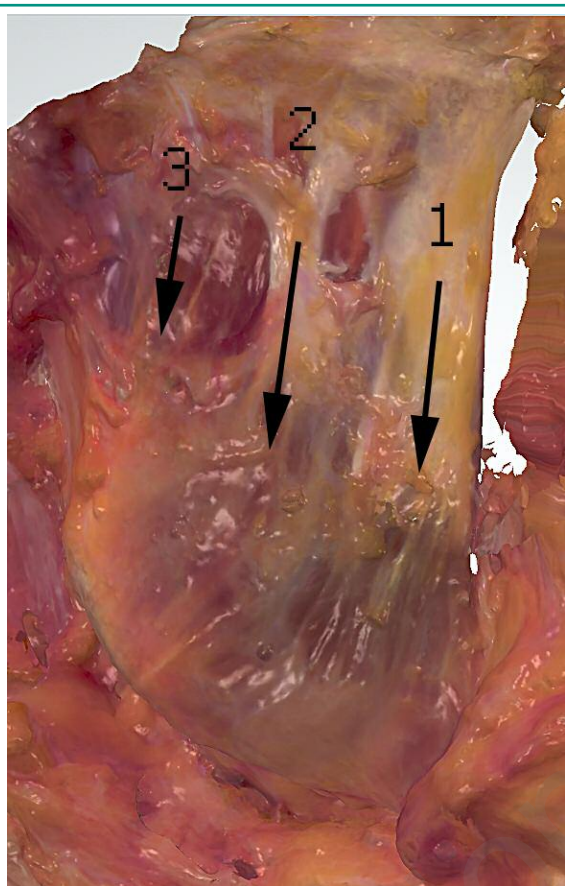


Figure 1
Masseter: superficial section (1); middle section (2); deep section (3).

dominant role in the performance of its functions, so much so that it has often been referred to as the most important mechanical part of the muscle. This is in fact an accurate description if one refers to its involvement in the regulating of the mechanical functions of the temporo-mandibular joint, but we do not believe it has been scientifically proven whether this description can be applied to its ability to generate a certain amount of force during the clenching of the arches or in a masticatory or swallowing cycle.

Materials and methods

This study has been conducted by use of an ultrasound machine (MicrUs ext-1H Teled Medical Systems

Milano) and a linear probe (L12-5140S-3 5-12 MHz 40 mm) which allowed us to record a video (DCM) comprised of 45 frames per second. The probe was fixed to a brace and the patient was asked to clench their teeth as hard as possible, obtain the muscle's maximum exertion, for 5 seconds three times, with 30 seconds intervals in between. Both right and left masseter muscles were analyzed.

During this procedure the patients were seating down on a dentists' chair with their head leaning on the headrest. The section of the muscle chosen is that in which the greatest possible expansion and the best view of the muscle layers during the contraction were visible. Said section was then marked on the patient's skin using an L shaped ruler that allows us to mark the bottom edge of the mandible. Then we applied to the resulting video a software (Mudy 1.7.7.2 AMID Sulmona Italy) for the analysis of muscle deformation patterns (contraction, dilatation, cross-plane, vertical strain, horizontal strain, vertical shear, horizontal shear, horizontal displacement, vertical displacement). During the contraction some sections of the muscle dilate and others clench. The strain, shear and displacement patterns describe the recorded phenomena analyzing the movement of the points that form the two-dimensional ultrasound image with respect to two axes, horizontal and vertical. The cross-plane pattern adds the third dimension indicating the movement of those same points in cross-section. The compression and dilatation patterns show the global movement of all the points on the two axes. The qualitative analysis of the deformation patterns was done by contouring the resulting chromatic areas and comparing them to the Region Of Interest (ROI) obtained from the underlying anatomical parts. The quantitative analysis was attained by examining the curves that show the strain in relation to the time (3-18). For the achievement of this result six ROI were created, one for each muscle layer (Figure 2). The number of videos of masseter muscles in contraction at maximum exertion due to dental clenching made during this research is around 12,000. Out of these we chose 1,200 videos which examine 200 patients (100 females, 100 males). The criteria for the choice of which videos to include in this case study are:

- a) the patients do not have any conditions or pathologies that affect the masticatory muscles or

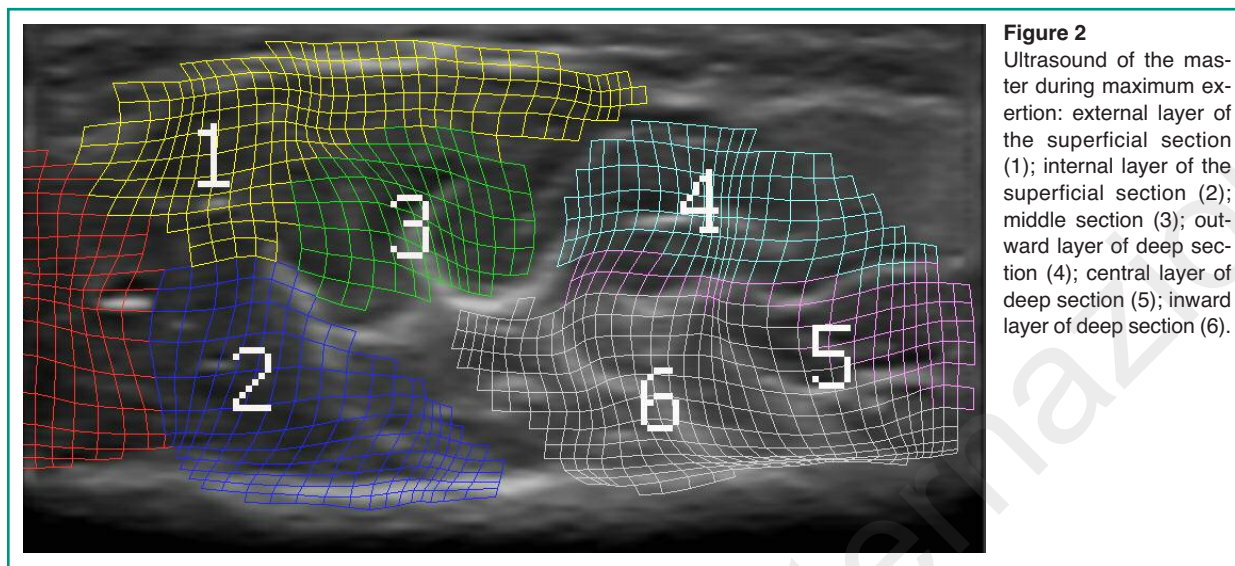


Figure 2
Ultrasound of the masseter during maximum exertion: external layer of the superficial section (1); internal layer of the superficial section (2); middle section (3); outward layer of deep section (4); central layer of deep section (5); inward layer of deep section (6).

the temporo-mandibular joints. No evident symptoms of DCM;

- b) at palpation the contractions were ranked 0-5 based on the following criteria, which take in consideration the stiffness of the muscle at the moment maximum exertion, the speed of the contraction, the ability to keep the muscle contract for 5 seconds and to repeat it for three times. The ranking was done by a single operator. (0): contraction absent; (1): weak contraction; (2): satisfactory contraction; (3): good contraction; (4): excellent contraction; (5): outstanding contraction;
- c) both masseters (left and right) show the same amount of force during contraction;
- d) alternate bilateral chewing.

The aim of this selection is to have a group based entirely on clinical criteria such as are normally considered satisfactory in order to consider the masticatory muscles in good health and in full functional efficiency. Only videos that ranked at 4 were taken into consideration.

Results

The analysis of deformation patterns allows us to assign to some of the layers a specific and repeatable behavior during a maximum exertion dental clenching.

Dilatation analysis pattern

In 92% of cases the parts that dilate the most are those corresponding to the middle head, to the central layer of the deep masseter and the internal layer of the superficial masseter and finally the deeper head (both outward and inward layers). The layer that appears to dilate the least is the upper layer of the superficial masseter, which makes sense given the thick aponeurosis that covers it.

Analyzing the measured curves we can see that the difference between the middle head and the central head of the deep masseter and the other layers of the muscle frequently rises above 20%. This part of the muscle seems to function as a sort of expansion chamber (Figure 3).

Deformation pattern “cross-plane”

We believe this name is to be given to the ability of the muscle to shorten itself during a contraction and represents its third dimension. These results and the ones of the previous pattern are superimposable each other. As the previous case, the apexes of the curves of the various layers do not match exactly. Our experi-

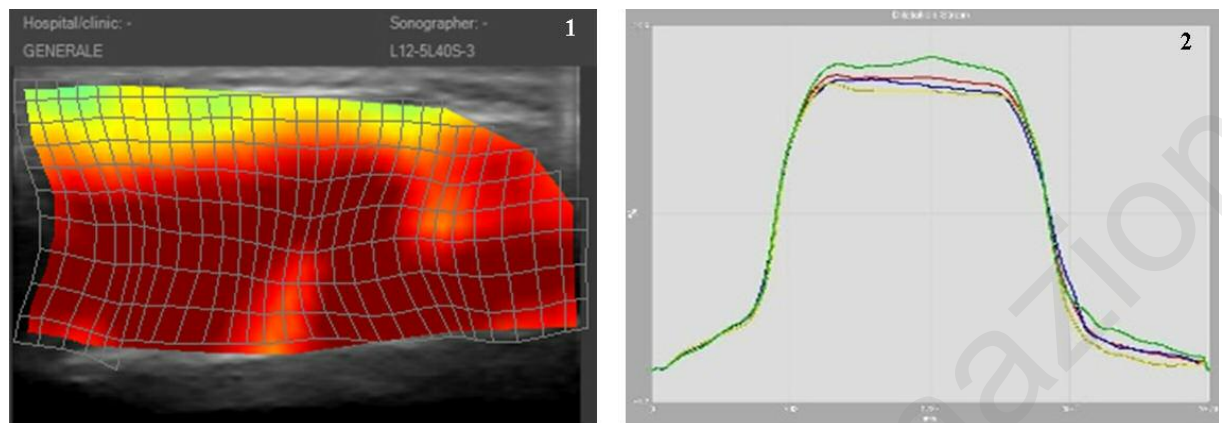


Figure 3
Dilation curves of the parts of the masseter muscle (1); maximum exertion contraction of the masseter (dilatation) (2).

ence shows that the dominant masseter, in patients whose chewing is unilateral or mostly unilateral, always presents a negative cross-plane well centered on the three parts that form the muscle (Figure 4).

Horizontal strain pattern

There is a number of interesting observations to make on this type of pattern analysis. During a maximum exertion clenching the deep masseter and the superficial masseter highlight a specific and repeatable behavior. The two layers that form the deep masseter twist themselves with opposite sign and direction, and the same do the outward and inward ends of the deep masseter. The central layer of the deep masseter ap-

pears to have little activity from this point of view. On the other hand the deep masseter and the superficial masseter twist themselves with identical sign and direction when observed as follows. The external layer of the superficial masseter and the inward layer of the deep masseter twist in the same direction, and the same happens to the internal layer of the superficial masseter and the outward layer of the deep masseter. In other words, it appears that the strain caused by the clenching of the dental arches implies the activation of a twisting control mechanism on the horizontal plane that regulates the effects of the notable expansion of the middle section of the muscle. This is a reasonable conclusion taking into account the force applied on the molars (can reach 500-900 newton per square centimeter) and the shape of the mandible (Figure 5).

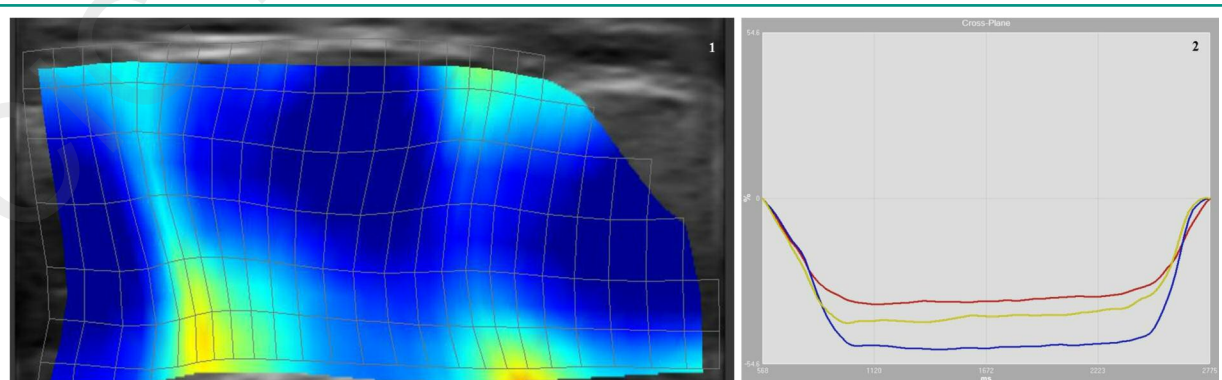


Figure 4
Maximum exertion contraction of the masseter (cross-plane) (1); curve strain/time (2).

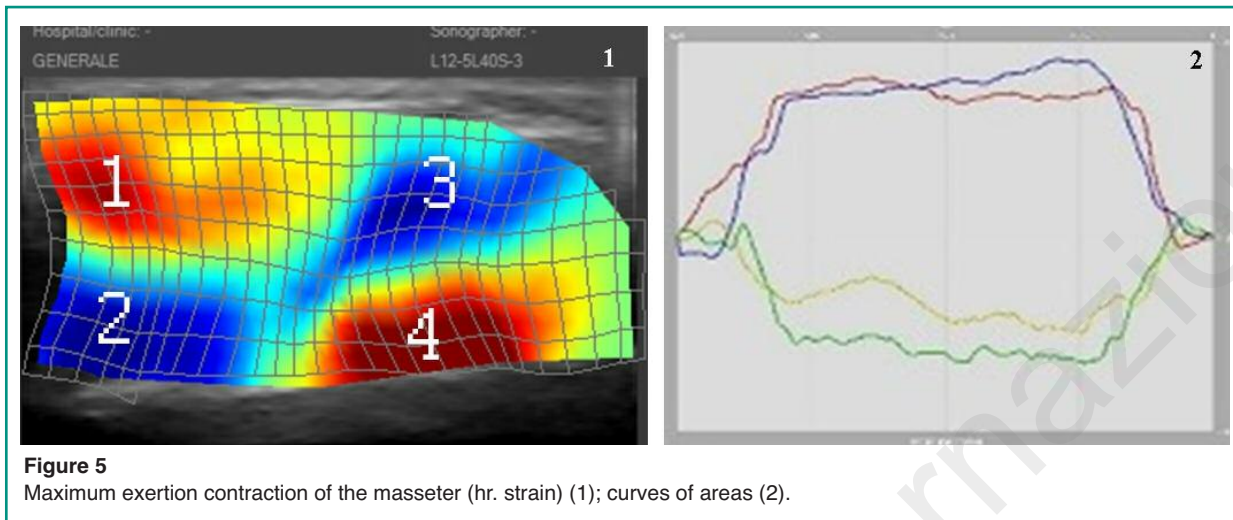


Figure 5
Maximum exertion contraction of the masseter (hr. strain) (1); curves of areas (2).

Horizontal displacement pattern

During an isometric contraction the anterior part of the muscle (superficial masseter) and the posterior part (deep masseter) suffer a movement of opposite sign in a dorsal-ventral direction. The middle masseter appears scarcely active in this pattern (Figure 6).

Vertical displacement pattern

Figure 7 shows the relative movement in the medio-lateral direction, to be interpreted as opposite in rela-

tion to the observations from the ultrasound video of the previous case.

Discussion

The analysis of the deformation patterns of the masseter allows us to observe how the six layers of the muscle have different and specific functions each, which vary depending on the applied force (application point, magnitude and direction) so that we find it impossible to assign to one of the three sections of the muscle a mechanical predominance. Therefore it appears that the three parts of the muscle have specific

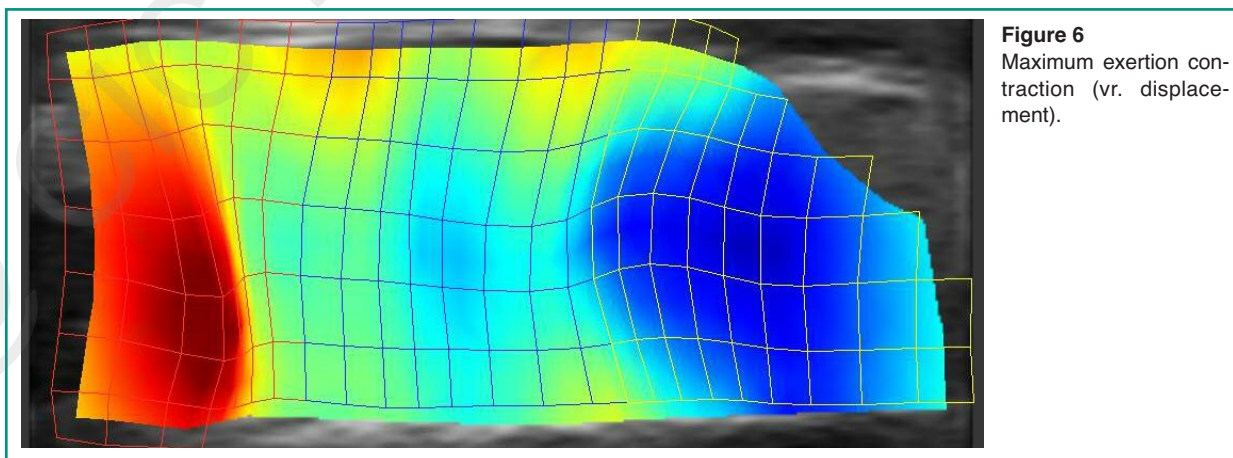


Figure 6
Maximum exertion contraction (vr. displacement).

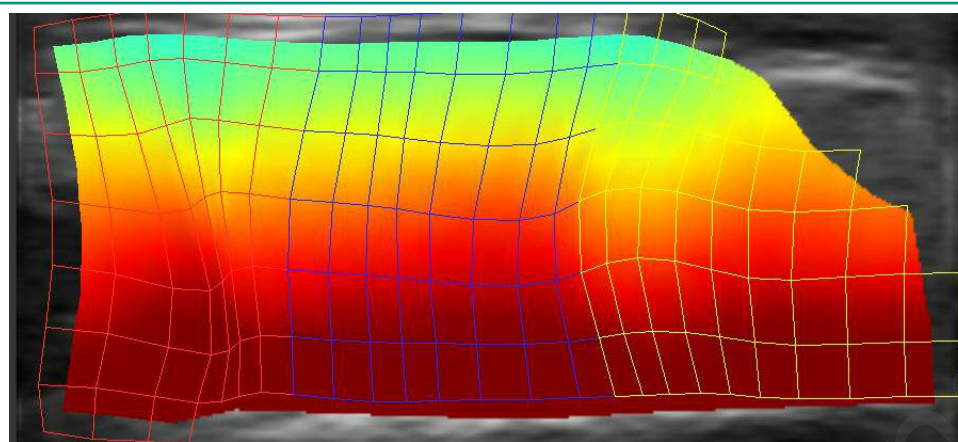


Figure 7
Maximum exertion contraction (hr. displacement).

and synergistic tasks. For example, the middle masseter and the central layer of the deep masseter seem capable of dilating to a greater extent than the rest of the muscle and therefore act as an expansion chamber. These normally present a cleaner texture in the ultrasound images, both on the surface and internally, which is characterized in the deeper region by the presence of several connective septi. The superficial and deep masseters appear to have an almost exclusive role in the control of the twisting on the horizontal plane, which could be explained by the extension towards the mediolateral direction of the insertion areas. The deformation pattern analysis based on ultrasound videos of the masseter muscle allows to perceive the existence of a complex system of biomechanical adjustments necessary for the management of the strain generated by wearing activities such as deglutition, mastication, phonation, hazardous movements done by habit and parafunctional activities such as teeth grinding. This is of paramount importance also in orthodontics and implantology (19-75). The stress which the masticatory organ is continually subject to depends on the application of extreme and variable external forces administered through teeth coming into contact during deglutition or the interposition of food during masticatory activities. The extreme dental morphology and multiple spatial relations, which for the teeth are established by the undertaking of the normal activities expected of the masticatory organ, presumably require sophisticated biomechanical adjustments done by the various areas and layers that form the masseter muscles. We believe that

the analysis of the strain can provide useful contributions to the study of the relationship between dental occlusion and masticatory muscle in terms of formation and management of functional and parafunctional stress and of the compensating effects for muscle and temporo-mandibular joint usury.

References

1. Busato A, Balconi G, Vismara V, Bertele L, Tonti G, Pedrizzetti G. Strain Analysis of Masseter Muscle by Ultrasound. *J Biol Regul Homeost Agents*. 2015;29:74-81.
2. Hylander WL, Ravosa MJ, Ross CF, Wall CE, Johnson KR. Symphyseal fusion and jaw-adductor muscle force: an EMG study. *Am J Phys Anthropol*. 2000; 112:469-92.
3. Rocha CP, Croci CS, Caria PH. Is there relationship between temporomandibular disorders and head and cervical posture? A systematic review. *J Oral Rehabil*. 2013;40:875-81.
4. Singh A. Optic Flow Computation: A Unified Perspective. Place: IEEE Comput. Soc. 1992.
5. Barron JL, Fleet DJ, Beauchemin SS. Performance of optical flow techniques. *International Journal of Computer Vision*. 1994;12:43-77.
6. Bohs LN, Geiman BJ, Anderson ME, Gebhart SC, Trahey GE. Speckle tracking for multi-dimensional flow estimation. *Ultrasonics*. 2000;38:369-75.
7. Malpica N, Santos A, Zuluaga MA, Ledesma MJ, Perez E, Garcia-Fernandez MA, Desco M. Tracking of regions-of-interest in myocardial contrast echocardiography. *Ultrasound Med Biol*. 2004;30:303-9.

8. Leitman M, Lysyansky P, Sidenko S, et al. Two-dimensional strain-a novel software for realtime quantitative echocardiographic assessment of myocardial function. *J Am Soc Echocardiogr.* 2004;17:1021-29.
9. Vannan MA, Pedrizzetti G, Li P, et al. Effect of cardiac resynchronization therapy on longitudinal and circumferential left ventricular mechanics by velocity vector imaging: description and initial clinical application of a novel method using high-frame rate B-mode echocardiographic images. *Echocardiography.* 2005;22:826-30.
10. Pedrizzetti G, Sengupta S, Caracciolo G, et al. Three-dimensional principal strain analysis for characterizing subclinical changes in left ventricular function. *J Am Soc Echocardiogr.* 2014;27:1041-50 e1.
11. Loram ID, Maganaris CN, Lakie M. Use of ultrasound to make noninvasive in vivo measurement of continuous changes in human muscle contractile length. *J Appl Physiol* (1985). 2006;100:1311-23.
12. Yoshii Y, Villarraga HR, Henderson J, Zhao C, An KN, Amadio PC. Speckle tracking ultrasound for assessment of the relative motion of flexor tendon and subsynovial connective tissue in the human carpal tunnel. *Ultrasound Med Biol.* 2009;35:1973-81.
13. Peolsson M, Lofstedt T, Vogt S, Stenlund H, Arndt A, Trygg J. Modelling human musculoskeletal functional movements using ultrasound imaging. *BMC Med Imaging.* 2010;10:9.
14. Korstanje JW, Schreuders TR, van der Sijde J, Hovius SE, Bosch JG, Selles RW. Ultrasonographic assessment of long finger tendon excursion in zone v during passive and active tendon gliding exercises. *J Hand Surg Am.* 2010;35:559-65.
15. Darby J, Hodson-Tole EF, Costen N, Loram ID. Automated regional analysis of B-mode ultrasound images of skeletal muscle movement. *J Appl Physiol* (1985). 2012;112:313-27.
16. Mor-Avi V, Lang RM, Badano LP, et al. Current and evolving echocardiographic techniques for the quantitative evaluation of cardiac mechanics: ASE/EAE consensus statement on methodology and indications endorsed by the Japanese Society of Echocardiography. *Eur J Echocardiogr.* 2011;12:167-205.
17. Pedrizzetti G, Kraigher-Krainer E, De Luca A, et al. Functional strain-line pattern in the human left ventricle. *Phys Rev Lett.* 2012;109:048103.
18. Lopata RG, van Dijk JP, Pillen S, et al. Dynamic imaging of skeletal muscle contraction in three orthogonal directions. *J Appl Physiol* (1985). 2010;109:906-15.
19. Lucchese A, Carinci F, Saggese V, Lauritano D. Orthodontic tooth movement and distraction osteogenesis. *European Journal of Inflammation.* 2012;10:49-54.
20. Lucchese A, Carinci F, Brunelli G. Skeletal effects induced by twin block in therapy of class II malocclusion. *European Journal of Inflammation.* 2012;10:83-87.
21. Mancini GE, Carinci F, Zollino I, Avantaggiato A, Lucchese A, Puglisi P, Brunelli G. Lingual orthodontic technique: A case series analysis. *European Journal of Inflammation.* 2011;9:47-51.
22. Mancini GE, Carinci F, Zollino I, Avantaggiato A, Puglisi P, Caccianiga G, Brunelli G. Effectiveness of self-ligating orthodontic treatment. *European Journal of Inflammation.* 2011;9:53-58.
23. Mancini GE, Carinci F, Avantaggiato IZ, Puglisi P, Caccianiga G, Brunelli G. Simplicity and reliability of invisalign® system. *European Journal of Inflammation.* 2011;9:43-52.
24. Avantaggiato A, Zollino I, Carinci F. Impact of orthodontic treatment on crestal bone resorption in periodontally compromised patients: A case series. *Acta Stomatologica Croatica.* 2010;44:188-94.
25. Busato A, Vismara V, Bertele L, Zollino I, Carinci F. Relation between disk/condyle incoordination and joint morphological changes: A retrospective study on 268 TMJs. *Oral Surgery, Oral Medicine, Oral Pathology, Oral Radiology and Endodontology.* 2010;110.
26. Danza M, Fromovich O, Guidi R, Carinci F. The clinical outcomes of 234 spiral family implants. *J Contemp Dent Pract.* 2009;10:E049-56.
27. Scarano A, Piattelli M, Carinci F, Perrotti V. Removal, after 7 years, of an implant displaced into the maxillary sinus. A clinical and histologic case report. *Journal of Osseointegration.* 2009;1:35-40.
28. Danza M, Zollino I, Guidi R, Carinci F. Computer planned implantology: Analysis of a case series. In: *Perspectives on Clinical Dentistry.* 2011:287-300.
29. Carinci F, Brunelli G, Danza M. Platform switching and bone platform switching. *J Oral Implantol.* 2009;35:245-50.
30. Grecchi F, Danza M, Bianco R, Parafioriti A, Carinci F. Computer planned implant-orthognathic rehabilitation: a case of one step surgical procedure with implants insertion, Le Fort I advancement, grafting and immediate loading. *J Osseointegration.* 2009;3.
31. Franco M, Rigo L, Viscione A, et al. CaPO4 blasted implants inserted into iliac crest homologue frozen grafts. *The Journal of oral implantology.* 2009;35:176-80.
32. Danza M, Guidi R, Carinci F. Comparison Between Implants Inserted Into Piezo Split and Unsplit Alveolar Crests. *Journal of Oral and Maxillofacial Surgery.* 2009;67:2460-65.
33. Grecchi F, Zollino I, Parafioriti A, Mineo G, Pricolo A, Carinci F. One-step oral rehabilitation by means of implants' insertion, Le Fort I, grafts, and immediate loading. *J Craniofac Surg.* 2009;20:2205-10.
34. Viscioni A, Franco M, Rigo L, Guidi R, Brunelli G, Carinci F. Implants inserted into homografts bearing fixed restorations. *Int J Prosthodont.* 2009;22:148-54.
35. Danza M, Scarano A, Zollino I, Carinci F. Evaluation of biological width around implants inserted in native alveolar crest bone. *Journal of Osseointegration.* 2009;1:73-76.
36. Danza M, Zollino I, Guidi R, Carinci F. A new device for impression transfer for non-parallel endosseous im-

- plants. Saudi Dental Journal. 2009;21:79-81.
37. Danza M, Zollino I, Carinci F. Comparison between implants inserted with and without computer planning and custom model coordination. J Craniofac Surg. 2009;20:1086-92.
38. Franco M, Viscioni A, Rigo L, Guidi R, Zollino I, Avantaggiato A, Carinci F. Clinical outcome of narrow diameter implants inserted into allografts. J Appl Oral Sci. 2009;17:301-6.
39. Danza M, Guidi R, Carinci F. Spiral family implants inserted in postextraction bone sites. Implant Dent. 2009;18:270-8.
40. Viscioni A, Franco M, Rigo L, Guidi R, Spinelli G, Carinci F. Retrospective study of standard-diameter implants inserted into allografts. J Oral Maxillofac Surg. 2009;67:387-93.
41. Carinci F, Brunelli G, Zollino H, et al. Mandibles grafted with fresh-frozen bone: An evaluation of implant outcome. Implant Dentistry. 2009;18:86-95.
42. Carinci F, Guidi R, Franco M, Viscioni A, Rigo L, De Santis B, Tropina E. Implants inserted in fresh-frozen bone: a retrospective analysis of 88 implants loaded 4 months after insertion. Quintessence Int. 2009;40:413-9.
43. Franco M, Tropina E, De Santis B, Viscioni A, Rigo L, Guidi R, Carinci F. A 2-year follow-up study on standard length implants inserted into alveolar bone sites augmented with homografts. Stomatologija. 2008;10:127-32.
44. Degidi M, Piattelli A, Carinci F. Clinical outcome of narrow diameter implants: a retrospective study of 510 implants. J Periodontol. 2008;79:49-54.
45. Degidi M, Piattelli A, Iezzi G, Carinci F. Do longer implants improve clinical outcome in immediate loading? Int J Oral Maxillofac Surg. 2007;36:1172-6.
46. Degidi M, Dapri G, Piattelli A, Carinci F. Evaluation of factors influencing resonance frequency analysis values, at insertion surgery, of implants placed in sinus-augmented and nongrafted sites. Clin Implant Dent Relat Res. 2007;9:144-9.
47. Degidi M, Piattelli A, Carinci F. Immediate loaded dental implants: comparison between fixtures inserted in postextractive and healed bone sites. J Craniofac Surg. 2007;18:965-71.
48. Degidi M, Piattelli A, Iezzi G, Carinci F. Retrospective study of 200 immediately loaded implants retaining 50 mandibular overdentures. Quintessence Int. 2007;38:281-8.
49. Degidi M, Piattelli A, Iezzi G, Carinci F. Immediately loaded short implants: analysis of a case series of 133 implants. Quintessence Int. 2007;38:193-201.
50. Degidi M, Piattelli A, Iezzi G, Carinci F. Wide-diameter implants: Analysis of clinical outcome of 304 fixtures. Journal of Periodontology. 2007;78:52-58.
51. Scarano A, Carinci F, Quaranta A, Di Iorio D, Assenza B, Piattelli A. Effects of bur wear during implant site preparation: an in vitro study. International journal of immunopathology and pharmacology. 2007;20:23-26.
52. Scarano A, Carinci F, Quaranta A, Iezzi G, Piattelli M, Piattelli A. Correlation between implant stability quotient (ISQ) with clinical and histological aspects of dental implants removed for mobility. International journal of immunopathology and pharmacology. 2007;20:33-36.
53. Degidi M, Piattelli A, Gehrke P, Felice P, Carinci F. Five-year outcome of 111 immediate nonfunctional single restorations. J Oral Implantol. 2006;32:277-85.
54. Degidi M, Piattelli A, Carinci F. Parallel screw cylinder implants: Comparative analysis between immediate loading and two-stage healing of 1005 dental implants with a 2-year follow up. Clinical Implant Dentistry and Related Research. 2006;8:151-60.
55. Degidi M, Piattelli A, Gehrke P, Carinci F. Clinical outcome of 802 immediately loaded 2-stage submerged implants with a new grit-blasted and acid-etched surface: 12-month follow-up. Int J Oral Maxillofac Implants. 2006;21:763-8.
56. Degidi M, Piattelli A, Felice P, Carinci F. Immediate functional loading of edentulous maxilla: a 5-year retrospective study of 388 titanium implants. J Periodontol. 2005;76:1016-24.
57. El Haddad E, Lauritano D, Carinci F. Interradicular septum as guide for pilot drill in postextractive implantology: a technical note. J Contemp Dent Pract. 2015;16:81-4.
58. Andreasi Bassi M, Lopez MA, Confalone L, Carinci F. Hydraulic sinus lift technique in future site development: clinical and histomorphometric analysis of human biopsies. Implant Dent. 2015;24:117-24.
59. Lopez MA, Andreasi Bassi M, Confalone L, Carinci F. Maxillary sinus floor elevation via crestal approach: the evolution of the hydraulic pressure technique. J Craniofac Surg. 2014;25:e127-32.
60. Lucchese A, Carinci F, Saggese V, Lauritano D. Immediate loading versus traditional approach in functional implantology. European Journal of Inflammation. 2012;10:55-58.
61. Danza M, Paracchini L, Carinci F. Tridimensional finite element analysis to detect stress distribution in implants. Dental Cadmos. 2012;80:598-602.
62. Fanali S, Carinci F, Zollino I, Brugnati C, Lauritano D. One-piece implants installed in restored mandible: a retrospective study. European Journal of Inflammation. 2012;10:19-23.
63. Scarano A, Murmura G, Carinci F, Lauritano D. Immediately loaded small-diameter dental implants: evaluation of retention, stability and comfort for the edentulous patient. European Journal of Inflammation. 2012;10:19-23.
64. Fanali S, Carinci F, Zollino I, Brugnati C, Lauritano D. A retrospective study on 83 one-piece implants installed in resorbed maxillae. European Journal of Inflammation. 2012;10:55-58.
65. Scarano A, Perrotti V, Carinci F, Shibli JA. Removal of

- a migrated dental implant from the maxillary sinus after 7 years: A case report. *Oral and Maxillofacial Surgery*. 2011;15:239-43.
66. Scarano A, Piattelli A, Assenza B, Carinci F, Donato LD, Romani GL, Merla A. Infrared thermographic evaluation of temperature modifications induced during implant site preparation with cylindrical versus conical drills. *Clinical Implant Dentistry and Related Research*. 2011;13:319-23.
67. Scarano A, Piattelli A, Assenza B, Sollazzo V, Lucchese A, Carinci F. Assessment of pain associated with insertion torque of dental implants. A prospective, randomized-controlled study. *International Journal of Immunopathology and Pharmacology*. 2011;24:65-69.
68. Traini T, Danza M, Altavilla R, et al. Histomorphometric evaluation of an implant retrieved from human maxilla after 13 years. *International Journal of Immunopathology and Pharmacology*. 2011;24:25-30.
69. Danza M, Riccardo G, Carinci F. Bone platform switching: a retrospective study on the slope of reverse conical neck. *Quintessence Int*. 2010;41:35-40.
70. Carinci F, Danza M. Clinical outcome of implants inserted in piezo split alveolar ridges: A pilot study. In: *Perspectives on Clinical Dentistry*. 2011:29-30.
71. Concolino P, Cecchetti F, D'Autilia C, et al. Association of periodontitis with GSTM1/GSTT1-null variants-A pilot study. *Clinical Biochemistry*. 2007;40:939-45.
72. Giannitelli SM, Basoli F, Mozetic P, et al. Graded porous polyurethane foam: A potential scaffold for oro-maxillary bone regeneration. *Materials Science and Engineering C*. 2015;51:329-35.
73. Giancotti A, Romanini G, Di Girolamo R, Arcuri C. A less-invasive approach with orthodontic treatment in beckwith-wiedeman patients. *Orthodontics and Craniofacial Research*. 2002;5:59-63.
74. Germano F, Bramanti E, Arcuri C, Cecchetti F, Cicciù M. Atomic force microscopy of bacteria from periodontal subgingival biofilm: Preliminary study results. *European Journal of Dentistry*. 2013;7:152-58.
75. Bramanti E, Maticena G, Cecchetti F, Arcuri C, Cicciù M. Oral health-related quality of life in partially edentulous patients before and after implant therapy: A 2-year longitudinal study. *ORAL and Implantology*. 2013;6:37-42.

Correspondence to:
Antonio Busato, DMD
Medica Libra
Via Gian Girolamo Savoldo 3
Milano (MI), Italy
Phone/fax: +39.02.6437937
E-mail: info@medica-libra.it