

MAXILLO-FACIAL PROSTHESIS (P.M.F): IN A CASE OF ORAL-NASAL COMMUNICATION POST-SURGERY AND POST-RADIOTHERAPY

L. OTTRIA¹, A. ZAVATTINI², F.M. CERUSO³, M. GARGARI^{1,3}

¹Department of Clinical Science and Translational Medicine, University of Rome "Tor Vergata", Rome, Italy

²PhD in "Material for Health, Environment and Energy", University of Rome "Tor Vergata", Rome, Italy

³Department of Dentistry "Fra G.B. Orsenigo-Ospedale San Pietro F.B.F.", Rome, Italy

SUMMARY

In patients with oral-nasal communication the absence of alveolar and/or palatal hard and soft tissue, or contraction resulting from previous surgical repair, needed prosthetic rehabilitation. This clinical report describes a treatment of an oral-nasal communication through a mixed prosthetic rehabilitation, fixed and removable, with attachments performed by EDM technique.

Key words: maxillo-facial prosthesis (P.M.F.), attachments, EDM technique.

Introduction

In adults, the task of the restorative dentistry is to restore the lost teeth and portion of the alveolar ridge to obtain function, esthetics, and alleviate deformities as much as possible (1). The treatment goal in the prosthetic rehabilitation of an oral-nasal communication is to enable the patient to function in society (2).

In patients with oral-nasal communication the absence of alveolar and/or palatal hard and soft tissue, or contraction resulting from previous surgical repair, needed prosthetic rehabilitation. Despite advances in surgical procedures, surgical reconstruction of maxillectomy or palate defects is not always possible because of the general health condition of the patient (3).

Depending on the extent and gravity of oral-nasal communication several functions and morphologic aspects such as speech, hearing, deglutition and mastication, developing of occlusion and craniofacial growth may be damaged and required intervention (4).

The trained prosthodontic has several methods to rehabilitated oral-nasal communication. A removable dental prosthesis such as obturator may be used for either temporary or permanent rehabilitation. In addition, the prosthesis can be easily to remove and to examine the surgical site so that tumor recurrence may be detected anytime (5, 6).

When a removable dental prosthesis is used to rehabilitated an oral nasal communication, particular attention must be given to the stability of the device. In fact a portion of the prosthesis must rest on soft tissues of the palate and may cause irritation, especially when the removable prosthesis hasn't a good stability (7).

For these reasons the treatment goal is to give an excellent stability to the removable prosthesis. A possible rehabilitation is to extract remaining teeth, and to place surgically dental implants in the maxilla to retain and give stability to a removable overdenture. But if the implant placement is not possible, we must give stability of the removable prosthesis in other way (8).

This clinical report describes a treatment of an oral-nasal communication through a mixed pros-

thetic rehabilitation, fixed and removable, with connections performed by EDM technique.

Case report

A 75-year-old man with an oral-nasal communication post-surgery and post-radiotherapy was examined in the UOC of Odontostomatologic Clinic (Department of Clinical Science and Translational Medicine, University of Rome "Tor Vergata", Rome, Italy).

Examination revealed a great palatal defect with oral-nasal communication (Fig. 1). The maxillary second premolars and the first and the second molars bilaterally were missing. Occlusion was compromised because of the loss of teeth, and the patient reported difficulty during chewing and indicated because maxillary deficiency some functional problems. Liquids and food entered the nasal cavity while drinking and eating, and also the phonation is difficult, because air escapes through the oral-nasal communication into the nasopharynx and nasal cavities, and oral pressure is not adequate for proper articulation and oral resonance. The patient don't solve these problems with a removable dental prosthesis with conventional attachments and gold crowns/resin (Fig. 2 a, b, c). Furthermore the prosthetic re-

habilitation, fixed and removable, was damaged and incongruous.

The new rehabilitation treatment of this oral-nasal communication was a mixed prosthetic rehabilitation (fixed and removable), a removable

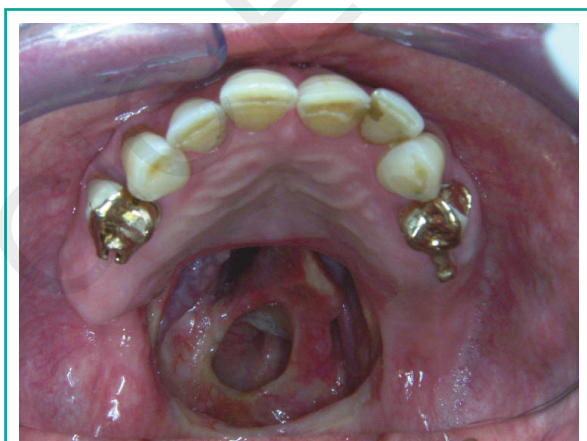

Figure 1
A great palate defect with oral nasal communication.

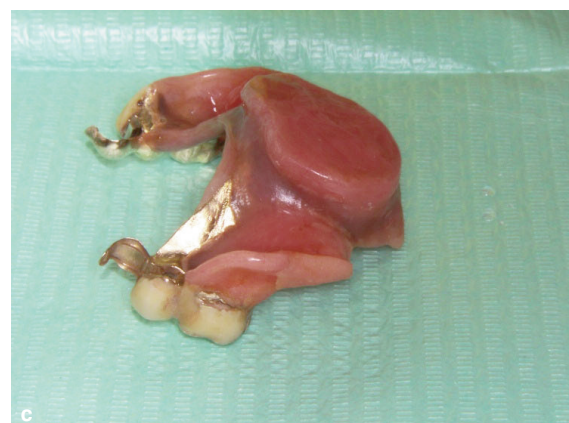
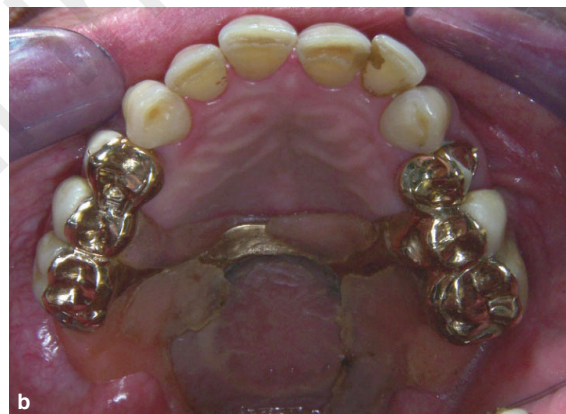
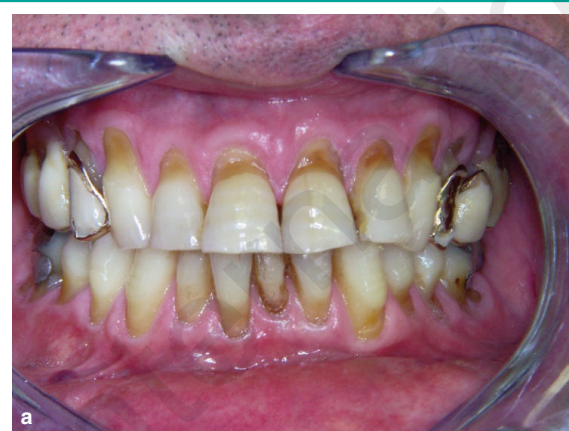Figure 2 a, b, c
Frontal view (a), occlusal view (b) of the removable dental prosthesis with conventional attachments and gold crowns/resin. The removable dental prosthesis (c).

obturator was planned with attachments performed by EDM technique.

As his gingival status was compromised, after the initial clinical examination patient was referred for periodontal therapy followed by x-rays assessment to analyze the remaining teeth. Tooth preparations was done on maxillary canine and 1st premolar in both side to receive PFM splinted crowns.

Precision attachments were performed by EDM technique on the distal surface of both premolars (Figs. 3, 4).

Then the impression for the obturator was made with irreversible hydrocolloid, and a gauze coated with petroleum jelly was placed over the palatal defect so that the impression material

could not enter the nasal cavity, as we can see on the developed model (Fig. 5) with the occlusal vertical dimension (VDO) in wax.

The removable dental prosthesis was made from a Co-Cr alloy with the latch attachments performed by EDM technique, heat-polymerized acrylic resin, and finally silicone in the central palatal portion of the obturator to obtain a better seal on the palatal defect (Fig. 6).

Figure 7 shows a detail of the PFM crowns and removable dental prosthesis with the own attachments performed by EDM technique: the latch of the removable prosthesis attachment will find location in the slot of the attachment of the PMF crowns, to retain and give stability to the removable dental prosthesis with obturator.

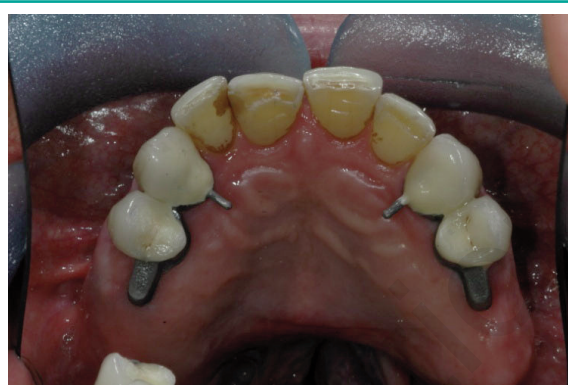

Figure 3
The intraoral test of the PFM splinted crowns with the attachments performed by EDM technique.

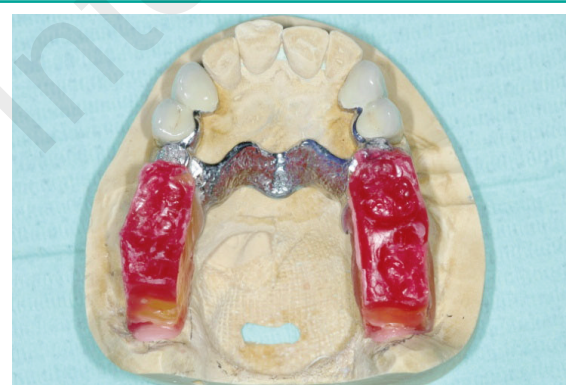

Figure 5
The model with the occlusal vertical dimension (VDO) in wax.

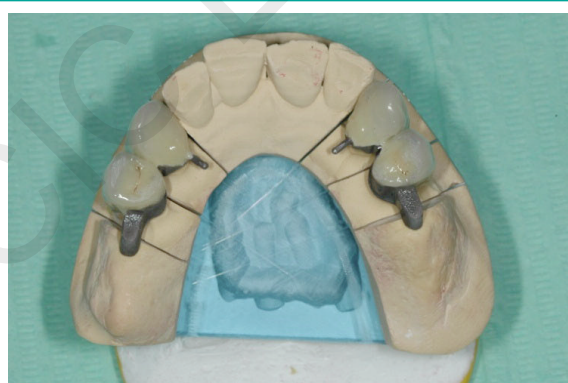

Figure 4
The master model and the PFM splinted crowns with the attachments performed by EDM technique.

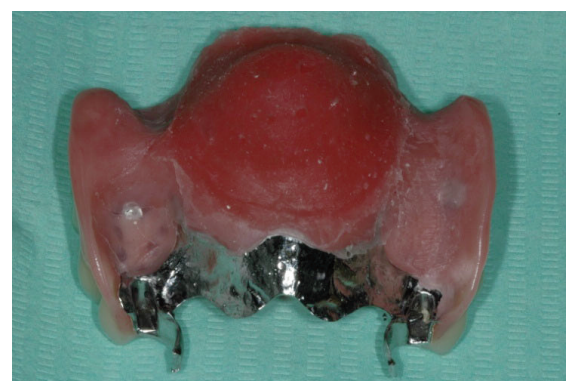


Figure 6
The removable dental prosthesis with the latch attachments performed by EDM technique and the obturator of the palatal defect.

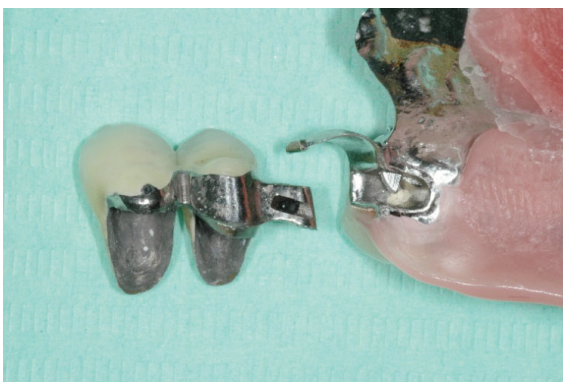

Figure 7

Detail of the PFM crowns and removable dental prosthesis with the own attachments performed by EDM technique: the latch of the removable prosthesis attachment will find location in the slot of the attachment of the PMF crowns.

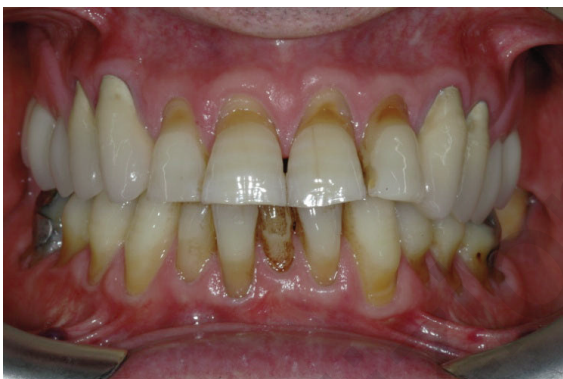

Figure 8

Frontal view of the final rehabilitation.

The fixed restorations were luted with polycarboxylate cement, and so the patient could wear the removable dental prosthesis as obturator with high aesthetic and functional value (Fig. 8).

The patient was shown oral home care techniques and placed on a 4-month periodontal maintenance schedule. To date follow-up of the prosthesis is 7 years.

Discussion

Rehabilitation of patients after surgical removal neoplasms in facial skeleton is one of the most

difficult therapies of the stomatognathic system in terms of re-establishing oro-nasal separation. For minor palatal defects a prosthetic rehabilitation can be achieved satisfactory using a palatal obturator, whilst bigger palatal defects represent a challenge for functional and aesthetic reconstruction (9).

Even in many cases an effective obturation of the oro-nasal cavity is achieved, in the relative majority, the prosthesis is usually rejected by the patient as being non-retentive and the outcome is a failure (10).

Retention and stability are affected by a variety of factors, including the level of direct/indirect retention promoted by the remaining teeth, defect size, available tissue surrounding the cavity and muscular control (11).

Generally, a conventional removable obturator uses various clasps as retention components. Clasps have a low capacity for retention and plastic deformation caused by cycles of insertion/removal may also lead to a rapid loss in retention and stability (12).

In many cases, precision attachments may be very useful. For the case described here, precision attachments performed by electrical discharge machine technique (EDM) have been used and represented an easy alternative to conventional clasps (male and female component). The position and the periodontal status of the abutment teeth are important factors that contribute to the absorption of stress generated by functional movement of the obturator and play an essential role in retaining and stabilizing the prosthesis (13). In the described case, the PMF crowns were splinted in order to better distribute the stresses at the abutment teeth.

Osseointegrated implants represent a new alternative in oral rehabilitation in patients with palatal defects or total and partial maxillectomies (14).

A combination of removable prosthesis and fixed implants could be considered but in certain difficult post-operative situations might be withdrawn.

Aydin et al. reported cases of osteonecrosis of the upper jaw in patients with osseointegrated implants follow radiotherapy and other authors hold that the irradiation of the jaw is a contraindication for the placement of an implant (15).

Indeed, in this clinical case, a combination of fixed and removable prosthesis was the treatment of choice and with education and appropriate recall, patient should be able to maintaining oral health.

References

1. Vojvodic D, Jerolimov P. The cleft palate patient: a challenge for prosthetic rehabilitation - clinical report. Quintessence Int. 2001;32:521-4.
2. Halkan TS, Gurell P, Filliz K. A method for positioning the premaxilla during impression making for a patient with bilateral cleft lip and palate: A clinical report. J Prosthet Dent. 2006;96:233-6.
3. Roumanas ED, Nishimura RD, Davis BK. Clinical evaluation of implants retaining edentulous maxillary obturator prostheses. J Prosthet Dent. 1997;77:184-190.
4. Lopes JF, Pinto JH, de Almeida AL, Lopes MM, da Silva Dalben G. Cleft palate obturation with Brånemark protocol implant-supported fixed denture and removable obturator. Cleft Palate Craniofac J. 2010;47(2):211-5.
5. Borlase G. Use of obturators in rehabilitation of maxillectomy defects. Ann R Australas Coll Dent Surg. 2000;15:75-89.
6. Curtis TA, Beumer J. Restoration of acquired hard palate defects: etiology, disability, and rehabilitation. In: Beumer J, Curtis TA, Marunick MT, editors. Maxillofacial rehabilitation: prosthodontic and surgical considerations. 1st ed. St Louis: Ishiyaku Euro-America; 1996:225-284.
7. Sema Murat, Ayhan Gurbuz, Abulfaz Isayev, Bahadır Dokmez, Unsun Cetin. Enhanced retention of a maxillofacial prosthetic obturator using precision attachments: Two case reports. Eur J Dent. 2012;6(2):212-217.
8. Flanagan D. An implant-retained maxillary overdenture to obturate a patient oronasal communication: a case report. J Oral Implantol. 2009;35(1):12-7.
9. Genden EM, Wallace D, Buchbinder D, Okay D, Urken ML. Iliac crest internal oblique osteomusculocutaneous free flap reconstruction of the postablative palatomaxillary defect. Arch Otolaryngol Head Neck Surg. 2001;127(7):854-61.
10. Goyal S, Goyal MK, Kallangan P. Magnetically retained extra oral prosthesis and maxillary interim obturator. Eur J Prosthodont. 2014;2:37-40.
11. Parr GR, Tharp GE, Rahn AO. Prosthodontic principles in the framework design of maxillary obturator prostheses. J Prosthet Dent. 1989;62(2):205-12.
12. Vallittu PK, Kokkonen M. Deflection fatigue of cobalt-chromium, titanium, and gold alloy cast denture clasp. J Prosthet Dent. 1995;74(4):412-9.
13. Keyf F. Review Obturator prostheses for hemimaxillectomy patients. J Oral Rehabil. 2001;28(9):821-9.
14. Mentag PJ, Kosinski TF. increased retention of a maxillary obturator prosthesis using osteointegrated intramobile cylinder dental implants: A clinical report. J Prosthet Dent. 1988;60(4):411-5.
15. Aydin C, Delilbaşı E, Yilmaz H, Karakoca S, Bal BT. Reconstruction of total maxillectomy defect with implant-retained obturator prosthesis. N Y State Dent J. 2007;73(6):38-41.

Correspondence to:

Dr. Liliana Ottria
Department of Clinical Sciences and Translational Medicine
University of Rome "Tor Vergata"
Via Montpellier 1, 00133 Rome, Italy
E-mail: liliana.ottria@uniroma2.it