

# RIGA-FEDE DISEASE AND NEONATAL TEETH

M. COSTACURTA, P. MATURO, R. DOCIMO

Department of Odontostomatological Science, University of Rome "Tor Vergata", Rome, Italy

## SUMMARY

**Aim.** The aim of this study is to present a case of Riga-Fede disease (RFD). RFD is a benign and uncommon mucosal disorder, characterized by an ulceration of the tongue, often caused by repetitive traumatic injuries due to backward and forward movements of the tongue over the mandibular anterior incisors.

RFD is most commonly associated with the eruption of primary lower incisor in older infants or natal-neonatal teeth in newborns.

**Methods.** A 2-month-old female infant was referred to our Paediatric Dentistry Unit for ulceration (13 mm diameter) on the ventral surface of the tongue and neonatal teeth.

The extraction of neonatal teeth was selected as treatment of choice, over more conservative treatments, for the rapid resolution of the lesion and for the limited risk of inadequate nutrients intake. The extracted teeth underwent a macroscopic/microscopic examination.

The complete healing of the lesion took 4 weeks; subsequently, the infant, revised at the 1-year follow-up visit.

**Conclusion.** Early detection of RFD is recommended because such lesions properly may induce deformity or mutilation of tongue, dehydration, inadequate nutrients intake by the infant and growth retardation.

**Key words:** Riga-Fede disease, traumatic lingual ulceration, neonatal teeth.

## Introduction

Riga-Fede disease (RFD) is a benign and uncommon mucosal disorder (1), characterized by an ulceration of the tongue, often caused by repetitive traumatic injuries due to backward and forward movements of the tongue over the mandibular anterior incisors (2).

The RFD was first identified, by Riga, an Italian physician, in 1881 and described in 1890 by Fede who performed the histological studies of the lesion (2).

The expression "traumatic ulcerative granuloma with stromal eosinophilia" (TUGSE) was coined by Elzay in 1983, referring to a chronic but self-limiting reactive ulcer of the oral mucosa (3,4).

In the oral pathology literature this lesion is known with different names.

In infants, this disease is also called traumatic lingual ulceration, eosinophilic granuloma and traumatic eosinophilic ulceration of the tongue and oral mucosa (1), sublingual fibrogranuloma, sublingual

growth in infants, traumatic atrophic glossitis (2,4,5).

Clinically, it commonly appears as an ulcer localized on the tongue (60% of the lesions), although also other areas such as lip, palate, gingiva, vestibular mucosa and floor of the mouth may be involved (3).

RFD can be asymptomatic or occasionally associated with pain. It is usually unifocal, though multifocal lesions and recurrences have been reported (3). Both sexes are equally affected (3).

Although common in infants (between 1 week and 1 year of age), RFD has been reported in older patients and in a patient with acquired immunodeficiency syndrome (6,7).

RFD is most commonly associated with the eruption of primary lower incisor in older infants (8,9) or natal-neonatal teeth in newborns (8,10).

The presence of teeth at birth or within a month post-delivery is a rare condition (11). Massler and Savara have divided these teeth into two groups according to the time of eruption (11):

- natal teeth: teeth present at birth

- neonatal teeth: teeth erupting during neonatal period (first 30 days of life).

The prevalence of natal-neonatal teeth ranges from 1:6000 to 1:800 and depends on the type of the study; the most common localization is the mandibular region of central incisors (85%), followed by maxillary incisors (11%), mandibular cuspids or molars (3%) and then maxillary cuspids or molars (1%) (11).

Most commonly, these teeth are precociously erupted from the normal complement of primary teeth (90-99%), only 1 to 10% of natal-neonatal teeth are supernumerary (11).

## Case report

A 2-month-old female infant was referred to our Paediatric Dentistry Unit of Fatebenefratelli S.Giovanni Calibita Hospital, University of Rome "Tor Vergata", for ulceration on the ventral surface of the tongue.

The ulceration was firstly noticed one month before her arrival at our hospital as small erosion. Over time, due to the enlargement of the ulceration, significant tissue loss occurred.

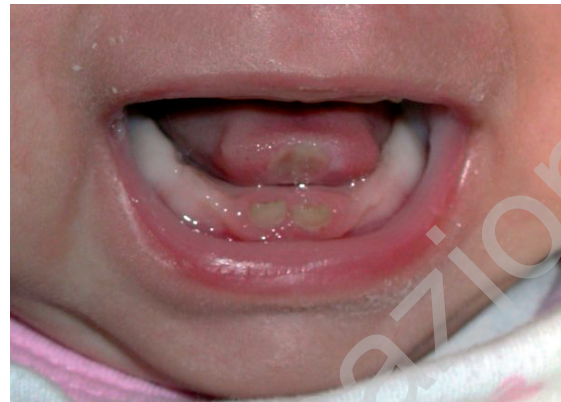Her parents reported that the child had inadequate nutrients intake, difficulties in suckling and intermittent bleeding on the distal surface of the tongue. The intraoral examination revealed two crowns of neonatal teeth in the mandibular anterior region with grade II mobility and an ulceration on the ventral surface of the tongue.

The physical examination revealed a circular lesion of 13 mm diameter, covered with a grey-white fibrinous plaque located on the anterior distal-ventral edge of the tongue, in contact with the lower central incisors (Fig. 1). Upon palpation of the area elicited a pain response from the patient.

The intraoral mucosa revealed no other lesions. No pathologic findings emerged from laboratory data, neurologic examination or clinical history.

The family history was negative also for developmental disorders and congenital syndromes.

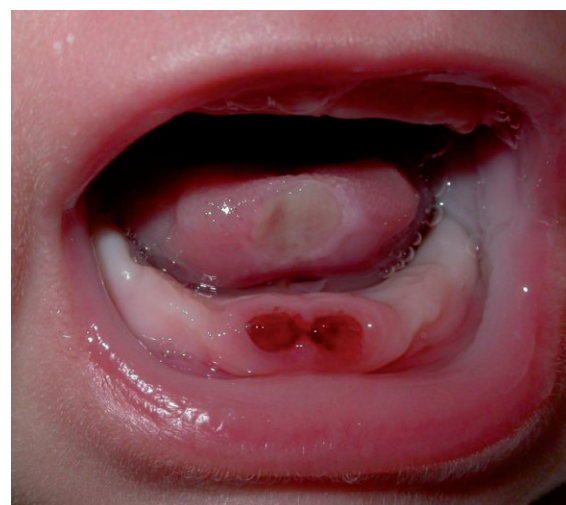The parents refused permission to perform a tongue biopsy therefore hystopathological examination could not be carried out. Based on the history and clinical features, a diagnosis of RFD was made.



**Figure 1**  
Riga-Fede disease and neonatal teeth.

The extraction of neonatal teeth was selected as treatment of choice, over more conservative treatments slowing the rate of healing, for the rapid resolution of the lesion and for the limited risk of inadequate nutrients intake. Furthermore the extraction was indicated to prevent a potential teeth ingestion or inhalation by the infant with the consequent penetration into airways and lungs, should the teeth become dislodged during nursing procedures due to their great mobility (grade II).

With the parental consent the extraction was carried out under topical local anaesthesia (Fig. 2) and was



**Figure 2**  
Riga-Fede disease and extraction sites of neonatal teeth.

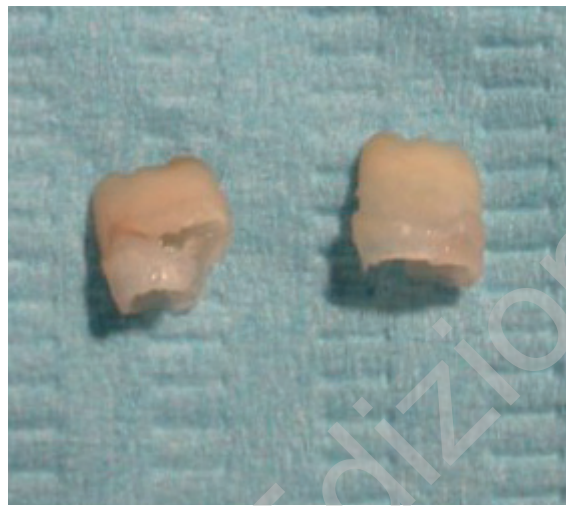followed by curettage of the socket to prevent the development of the dental papilla cells (“residual natal tooth”) to continue, as reported by Ooshima (12) and Tsubone (13).

The teeth showed normal size-shape, whitish opaque colour and absence of root formation (Fig. 3).

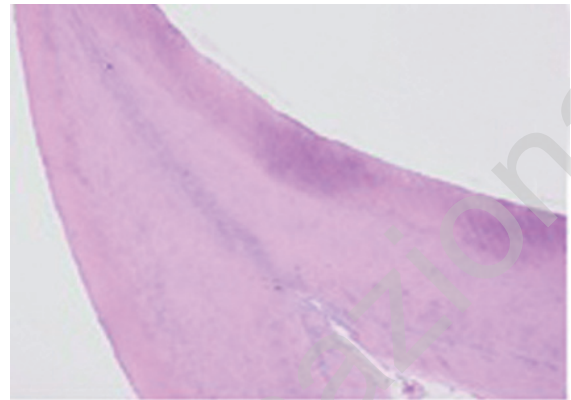
The extracted teeth underwent a microscopic examination. Histological analysis showed immature crowns but an overall well-structured layer (enamel-dentin layer, dentinal tubules) (Fig. 4).

The complete healing of the tongue lesion took 4 weeks (Fig. 5).

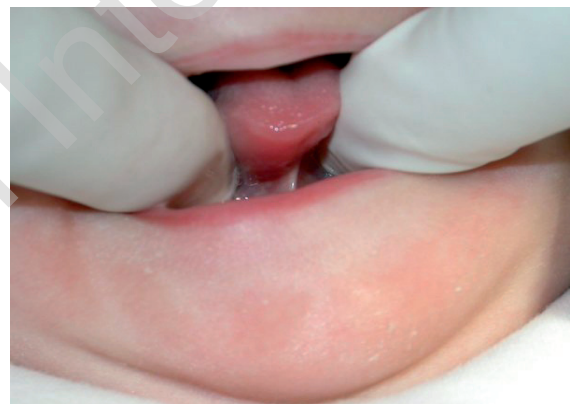
The infant, revised at the 1-year follow-up visit, presented an healthy mucosa of the tongue (Fig. 6).



**Figure 3**  
Neonatal extracted teeth.



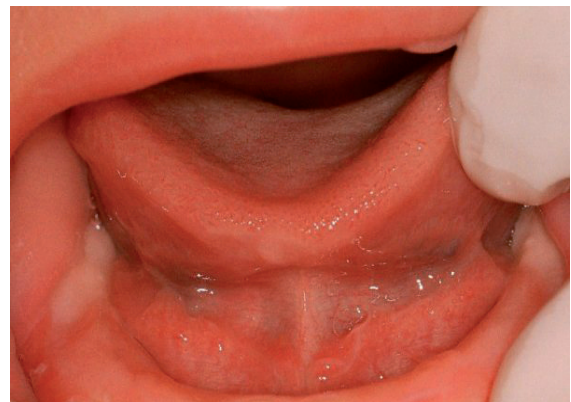**Figure 4**  
Histological analysis of neonatal extracted teeth.



**Figure 5**  
Follow-up at 4 weeks.

## Discussion and conclusion

RFD is a reactive traumatic mucosal disease characterized by persistent ulcerations of the oral mucosa. It develops as a result of repetitive trauma of the tongue by the mandibular incisor teeth during continual protrusive and retrusive movements (1,5). The condition is most commonly observed in newborns and the beginning of the lesions usually coincides with the eruption of the primary teeth; however, the symptoms can be observed immediately after birth with natal and neonatal teeth (1).



**Figure 6**  
Follow-up at 1 year.

RFD is a rare clinicopathological entity with unknown aetiology, although a relation with chronic trauma due to the teeth has been proposed by many authors (1,8,10). Narang et al. described the constant traction due to tongue-tie as another cause in addition to the trauma caused by the teeth (14).

The effect of trauma was demonstrated in experimental studies with rats (3). Tang et al. (1,15) proposed that the trauma is only a contributing factor in the development of RFD, that could lead to viral and toxic agents penetrating in the sub mucosa and into the traumatic area causing inflammatory reaction and tissue loss.

Any mucosal surface can be affected in the oral mucosa; however, the tongue is the most common location as in the reported cases (1,5,8). Oral lesions usually appear as ulcerations in the midline of the tongue ventral surface (1).

Microscopic findings mainly show an inflammatory infiltrate composed of numerous eosinophils with lymphocytes, macrophages, plasma cells and mast cells (2).

With regard to RFD treatment, several management options have been reported. They may be used alone or in combination (2,4,5,8,9,16):

- a) cellulose film or other protective dental appliance;
- b) oral disinfectant;
- c) corticosteroids;
- d) teething ring;
- e) smoothing the incisal edges;
- f) small increment of restorative material to the incisal edges;
- g) dental extraction.

RFD may be considered as a benign condition in healthy infants, but it may be associated with other serious neurologic disorders (2,5,9), including familial dysautonomia (Riley-Day syndrome), congenital autonomic dysfunction, microcephaly (5), the Lesh-Nyhan syndrome (1) and the Tourette's syndrome (17).

Some authors stated that RFD occurs almost exclusively in children with cerebral palsy (5).

Domínguez-Cruz et al. (18) proposed a new classification of RFD, dividing the disease into precocious and late. The "precocious RFD" is associated with natal-neonatal teeth, it appears in the first 6 months of the life and has no correlation with neurological disorders; the "late RFD" typically appears after 6-

8 months of life, with the first dentition, and may be related to neurological disorders (18).

Early detection of RFD is recommended to diagnose and treat these severe diseases, but also for otherwise healthy infants (2).

Moreover, a failure to diagnose or treat such lesions properly may induce deformity or mutilation of tongue, dehydration, inadequate nutrients intake by the infant and growth retardation (2).

In conclusion, as RFD often mimics many oral malignant and benign disorders, the differential diagnosis is important (1,2).

Clinical presentation, laboratory data, biopsy and follow-up can help in the differential diagnosis.

In fact, ulceration of the tongue may also be due to other causes, including bacterial or mycotic infections, allergy and immunologic diseases, tumours (traumatic neuroma, granular cell myoblastoma, lymphoma, lymphangioma, salivary gland tumours, metastatic tumours) (3), genetic disorders (2), primary syphilis, tuberculosis, agranulocytosis (1).

## References

1. Ceyhan AM, Yildirim M, Basak PY, Akkaya VB, Ayata A. Traumatic lingual ulcer in a child: Riga-Fede disease. *Clin Exp Dermatol* 2009;34(2):186-8.
2. Baroni A, Capristo C, Rossiello L, Faccenda F, Satriano RA. Lingual traumatic ulceration (Riga-Fede disease). *Inter J Dermatol* 2006;45(9):1096-7.
3. Joseph BK, BairavaSundaram D. Oral traumatic granuloma: report of a case and review of literature. *Dent Traumatol* 2010;26(1):94-7.
4. Elzay RP. Traumatic ulcerative granuloma with stromal eosinophilia (Riga-Fede's disease and traumatic eosinophilic granuloma). *Oral Surg Oral Med Oral Pathol* 1983;55:497-506.
5. Baghdadi ZD. Riga-Fede disease: association with microcephaly. *Int J of Paediatr Dent* 2002;12:442-5.
6. Taghi A, Motamedi MK. Riga-Fede disease: A histological study and case report. *Indian J Dent Res* 2009;20:227-9.
7. Santos Cunha V, Rocha Zanol JD, Sprinz E. Riga-Fede-like disease in an AIDS patient. *J Int Assoc Physicians AIDS Care (Chic III)* 2007;6:273-4.
8. Hegde RJ. Sublingual traumatic ulceration due to neonatal teeth (Riga-Fede disease). *J Indian Soc Pedo Prev Dent* 2005;23:51-2.

9. Slayton RL. Treatment alternatives for sublingual traumatic ulceration (Riga-Fede disease). *Pediatr Dent* 2000;22(5):413-4.
10. Goho C. Neonatal sublingual traumatic ulceration (Riga-Fede disease): reports of cases. *ASDC J Dent Child* 1996;63(5):362-4.
11. Rao RS, Mathad SV. Natal teeth: case report and review of literature. *J Oral MaxilloFac Pathol* 2009;13(1):41-6.
12. Ooshima T, Mihara J, Saito T, Sobue S. Eruption of toothlike structure following the exfoliation of natal tooth: report of a case. *ASDC J Dent Child* 1986;53:275-8.
13. Tsubone H, Onishi T, Hayashibara T, Sobue S, Ooshima T. Clinico-pathological aspects of a residual natal tooth: a case report. *J Oral Pathol Med* 2002;31:239-41.
14. Narang T, De D, Kanwar AJ. Riga-Fede disease: trauma due to teeth or tongue tie? *J Eur Acad Dermatol Venereol* 2008;22(3):395-6.
15. Tang TT, Glichklich M, Hodach AE. Ulcerative eosinophilic granuloma of the tongue. A light- and electron-microscopic study: *Am J Clin Pathol* 1981;75:420-5.
16. Jariwala D, Graham RM, Lewis T. Riga Fede disease. *Br Dent J* 2008; 204(4):171.
17. Choi SC, Park JH, Choi YC, Kim GT. Sublingual traumatic ulceration (a Riga-Fede disease): report of two cases. *Dent Traumatol* 2009;25(3):e48-50.
18. Domingues-Cruz J, Herrera A, Fernandez-Crehuet P, Garcia-Bravo B, Camacho F. Riga-Fede disease associated with postanoxic encephalopathy and trisomy 21: a proposed classification. *Pediatr Dermatol* 2007; 24(6):663-5.

---

*Correspondence to:*

Prof. Raffaella Docimo  
Via Montpellier 1  
00133 Rome, Italy  
Phone/Fax: 0620900265  
E-mail: raffaella.docimo@ptvonline.it